



**Medivoh is the exclusive distributor  
of MIRRAGEN® in Ukraine**

MIRRAGEN® is manufactured in Rolla, Missouri,  
USA by our partner ETS Wound Care

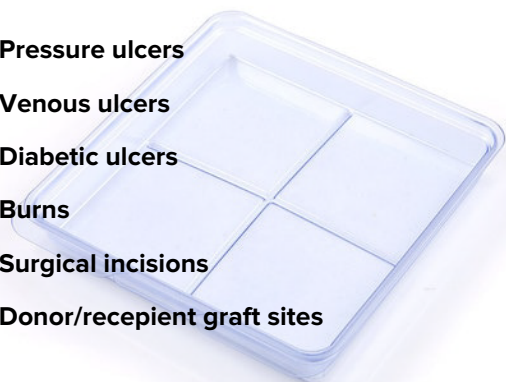


We dream and strive to ensure that the best health care products are available in Ukraine.  
Having the fastest possible supply chain, we can supply you our products immediately, at your request.

**MIRRAGEN®  
Revolutionary Wound Care Solution**

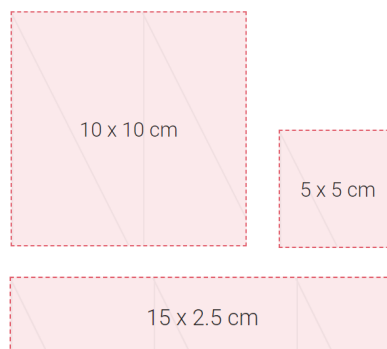
Indicated for professional use for partial and full-thickness  
wounds, such as:

- ✓ **Pressure ulcers**
- ✓ **Venous ulcers**
- ✓ **Diabetic ulcers**
- ✓ **Burns**
- ✓ **Surgical incisions**
- ✓ **Donor/receptient graft sites**



**MIRRAGEN® product sizing**

MIRRAGEN® is available in various sizes and shapes. For full  
prescribing information please refer to the Technical Guide.

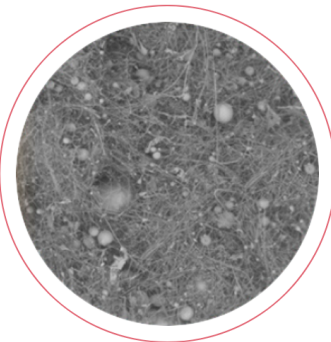


## MIRRAGEN® fibrous structure


The fibrous structure of MIRRAGEN® allows it to wick fluid away from the wound bed and control the moisture content to facilitate the wound healing response. During the healing process, MIRRAGEN® is absorbed by the surrounding tissue. Product ability to absorb moisture makes it possible to use MIRRAGEN® on strongly exuding wounds with repeated use every 3-7 days or as needed.



MIRRAGEN®



MIRRAGEN® - 50X Magnification

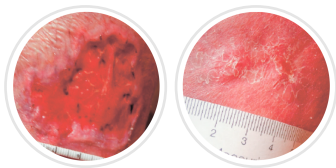


MIRRAGEN® - 800X Magnification

Due to MIRRAGEN® ability to absorb ~ 0.5 ml / sq. cm, applied product with size of 10 × 10 cm can contain approximately 50 ml of liquid.

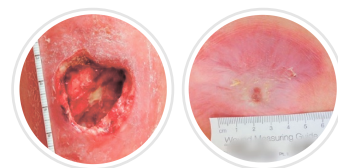
## MIRRAGEN® - unique biomaterial for the treatment of complex wounds

MIRRAGEN® consists exclusively of biodegradable borate glass fibers and particles. It is a flexible and formable wound matrix, the shape of which can easily be adjusted to the geometry of the wound.



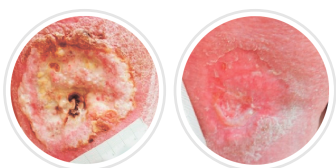
### Lower leg wounds

Lower leg wound that previously failed all other methods of treatment.  
Wound age when treatment started: 3 months



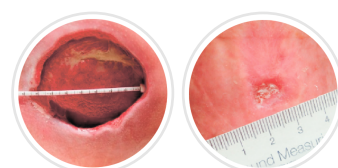
### Deep Traumatic Injury / Venous Insufficiency

Diabetic, PVD, PAD, neuropathy; previous chronic wounds and recurring leg infections.  
Age of wound when treatment started: 2 months



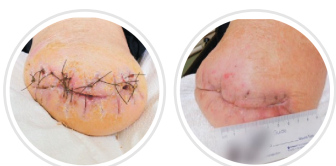### Venous Ulcers

Female (mid 40's) with hypertension, hypothyroidism; denies other health concerns.  
Age of wound when treatment started: 2 months



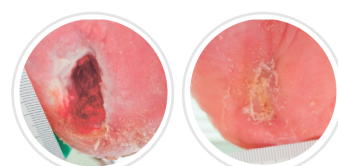
### Sacral Wounds

44-year-old male paraplegic with sacral ulcer over bony prominence (lower back, tail bone).  
Age of wound when treatment started: unknown



### Surgical Sites

Male diabetic with vascular deficiency amputee requiring stump revision (below knee).  
Age of wound when treatment started: 2 months



### Diabetic Foot Wounds

Male diabetic with peripheral neuropathy; hypertension, renal failure requiring dialysis 3x weekly; chronic pain with disk disease.  
Age of wound when treatment started: ~2 years

Mirrager — Effective treatment for healing chronic wounds